General practice emergencies in ophthalmology

Stephen J Best FRANZCO

Introduction

As in many other branches of medicine, obtaining a fast and accurate history is paramount in the formulation of differential diagnoses, and directing clinically guided appropriate investigations. When considering visual function, a history of sudden complete loss of visual function suggests vascular pathology whilst a history of slow decline over weeks is more suggestive of a compressive lesion. This should be compared to the rapid loss of vision that might occur over the timeframe of a few days, such as an inflammatory condition, e.g. optic neuritis.

However, anterior segment disease involving the eye will often be obvious to the patient and other observers. A red eye without loss of visual function is usually more benign than conditions that effect visual function.

Stephen Best has a part-time consultant appointment at Auckland Hospital Eye Department, and also practises from Auckland Eye, a subspecialty group ophthalmology practice. He is an Otago Medical School graduate and, after registrar training in the Auckland/Waikato programme, spent two years in Philadelphia completing subspecialty training in Glaucoma and Neuro-ophthalmology at Wills Eye Hospital. Since returning to Auckland in 1992 he has maintained subspecialist interest in both public and private practice. He has been involved in regular undergraduate and postgraduate ophthalmology teaching, and continues his role as a Part I examiner for the RANZCO.

Tools of the trade

a. Snellen Chart appropriately illuminated
b. Pinhole device to check for potential refractive visual loss
c. Flashlight to check for pupillary responses (some may have a cobalt blue filter attachment to stimulate fluorescein stain when examining cornea for epithelial defects)
d. Fluorescein stain...best option is paper strips impregnated with stain
e. Ophthalmoscope (with reliable batteries)
f. Topical anaesthetic agent (Benoxinate Minims Oxybuprocaine HCl 0.4%)

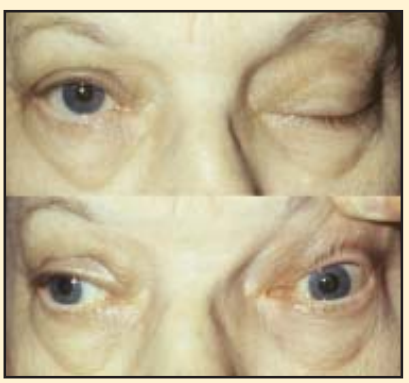

Figure 1. Pupil involved third cranial nerve lesion on left. Note ptosis and on elevation of the lid the pupil is dilated and the typical abnormal motility.

1. Complete third nerve palsy

Complete ptosis with loss of function of all extra-ocular muscles except CN IV, and CN VI. The eye will be deviated down and out, when the lid is manually elevated.

If the pupil is dilated, and does not react to light, consider acute compressive lesions – a posterior communicating artery aneurysm needs to be excluded by urgent neuro-radiological investigations. The risk of sub-arachnoid haemorrhage with significant morbidity/mortality requires immediate referral to hospital.

A pupil spared CN III palsy may occur due to micro-vascular disease (diabetes/hypertension). Often also presents with headache. Usually spontaneously recovers over three months. However these patients should be checked at one week to exclude progression into a pupil involved CN III lesion as above. (Figure 1)

Figure 2. Papilloedema with elevated optic disc and haemorrhages. Both optic discs were involved.

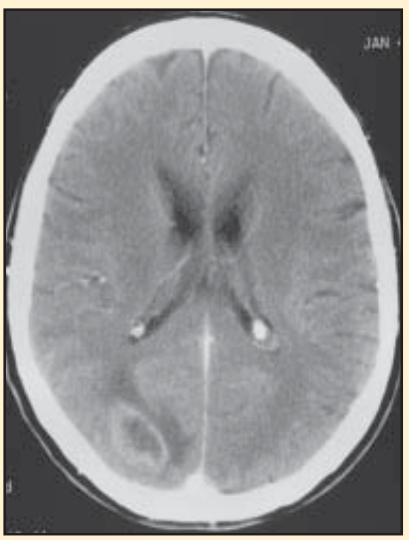

Figure 3. Space occupying lesion in posterior cerebral area responsible for the disc swelling seen in Figure 2 above.

Figure 4. Arteritic ischaemic optic neuropathy due to Giant Cell Arteritis. Note the pallid swelling of the optic disc, and small disc haemorrhage. This appearance carries a poor visual prognosis and this patient developed bilateral blindness within two days!

2. Papilloedema

Swollen optic nerve heads due to raised intra-cranial pressure. The disc will have blurred margins and usually haemorrhages. Visual acuity is most often normal. Pupillary responses will be normal, and the eye appears quiet. Typical history might include early morning headache, and other neurological symptoms.

Urgent neuro-radiological imaging is required within 24–48 hours and appropriate specialist referral. (Figures 2 and 3)

3. Giant Cell Arteritis (GCA) / Temporal Arteritis

In any patient over the age of sixty years who presents with a history of sudden alteration in vision consider this diagnosis, which is potentially treatable to salvage vision. A history of fleeting loss of vision or intermittent diplopia is highly suspicious, especially if accompanied by other protean manifestations of this condition including headache, scalp tenderness, jaw claudication, weight loss, malaise, fever, and polymyalgia rheumatica. Urgent full blood count, erythrocyte sedimentation rate (ESR) and C reactive protein (CRP) levels are required. If the clinical picture is overwhelmingly suggestive of GCA, then steroid treatment should be instituted immediately; most ophthalmology services would treat with IV methylprednisolone, and await the results from the temporal artery biopsy. Unfortunately there are some patients who will still lose vision even when treated with high initial doses of prednisone. Biopsy positive patients with visual symptoms should be maintained on oral prednisone for at least one year, and monitored by serial blood tests. (Figure 4)

4. Sudden loss of vision

The differential diagnosis includes retinal arterial occlusive disease and the potential association of cerebro-vascular accidents; retinal venous occlusive disease and often associated hypertension and primary open angle glaucoma; and retinal detachment which is seen more frequently in patients with myopia (short-sightedness with glasses that appear to minify the eye), or previous cataract surgery. Vascular occlusive disease presents with painless loss of vision often first noted in the early morning. The hallmark symptoms of retinal detachment are flashes and floaters with a shadow in the visual field. A similar history is seen in patients with posterior vitreous detachment due to vitreous syneresis as part of natural ageing processes which also increases the risk of retinal detachment. Examination will reveal loss of visual acuity that does not improve with pinhole testing, and typically a relative afferent pupillary defect will be present; swinging flashlight test will demonstrate dilation of the pupil on the affected side relative to the normal pupil. Referral to specialist care should be within 24–48 hours as modern vitreo-retinal surgery offers a good prospect for retention of vision in the case of retinal detachment and evaluation of vascular-occlusive disease is also important in terms of systemic and ocular associations. (Figures 5 and 6)

5. Acute Iritis

Patients with anterior uveitis (iritis) often present with minimal visual dysfunction, but ocular discomfort and photophobia. The clinical features include conjunctival hyperaemia around the corneal limbus

Figure 5. Central retinal artery occlusion. Note the 'cherry red macular' and pale infracted retinal nerve fibre layer.

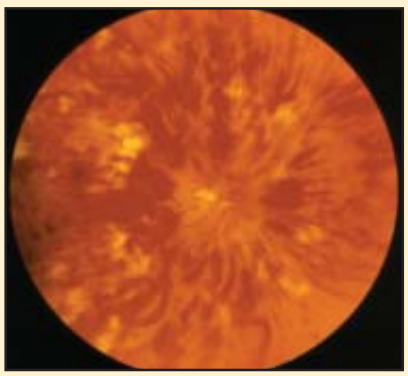

Figure 6. Central retinal vein occlusion. This is a severe example with gross retinal haemorrhages, and long term the patient developed neovascular glaucoma and subsequent loss of vision.

Figure 7. Acute angle closure glaucoma. Typical features are diffuse conjunctival hyperaemia, corneal oedema, and the mid dilated pupil.

(circumciliary injection), and pupillary irregularity due to the formation of posterior synechia when the inflamed iris becomes connected to the anterior surface of the lens. The diagnosis can only be confirmed by slit-lamp examination, so referral to specialist care within a 24–48 hour timeframe is appropriate. Treatment with a topical steroid and mydriatic is instituted bringing rapid resolution in symptoms. Bilateral involvement suggests underlying systemic disease but most commonly this condition is idiopathic. Long-term ophthalmic complications include cataract formation and secondary glaucoma. (Figure 7)

6. Acute angle closure glaucoma

The typical history is of visual blurring with haloes around lights, and peri-ocular pain with associated nausea and vomiting. Some patients will present with a history of intermittent symptoms often worse in the evening, suggesting chronic episodes of angle closure. The most commonly associated eye condition is hyperopia (long-sightedness with glasses that appear to magnify the eye). The usual clinical signs are generalised conjunctival hyperaemia, corneal oedema, and a mid-dilated pupil. The eye will feel hard to palpation through the lid. If left untreated, vision loss will ensue; the emergency treatment includes the use of topical hypotensive agents (beta blocker if not contra-indicated, alpha agonists, and pilocarpine) and, if available, systemic acetazolamide. These patients should be referred urgently to ophthalmologic specialist care within 12 hours. The usual treatment will include, in addition to the above agents, topical steroids and laser surgical iridotomy to both eyes (the unaffected eye having a prophylactic procedure). Some patients may require additional surgical management. (Figure 8)

7. Acute conjunctivitis

Although the patient presents with obvious ocular hyperaemia, visual function is usually unaffected. Watery discharge suggests viral etiology whilst a purulent discharge suggests bacterial etiology. One of the more common viral agents implicated is adenovirus which will often be associated with upper respiratory symptoms, lymphadenopathy, and a history of contact with other patients with similar disease reinforcing the potential contagious nature of this condition that mandates careful attention to hygiene. Patients with conjunctivitis should have eye swabs taken for micro-biology and virology. Treatment with topical antibiotics is appropriate and modification based on results from the swab as necessary. Viral conjunctivitis may often take several days to spontaneously settle. Whilst the most common cause of poor response to treatment relates to under treatment, initial treatment should be topical antibiotics one to two hourly! Topical mydriatics may reduce ocular discomfort, but cause undesirable blurred vision. Referral for specialist evaluation is indicated by poor response to treatment over several days and not infrequently other conditions such as iritis may be the culprit.

8. Corneal ulceration

If a patient presents with a brief history of ocular discomfort unrelated to trauma, lacrimation, and minimal visual disturbance, the possibility of corneal disease is easily confirmed by the use of fluorescein stain with appropriate cobalt blue light excitation (either from handheld flashlight or ophthalmoscope filter). A typical herpetic ulcer will have a

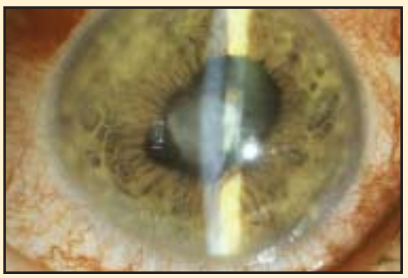

Figure 8. Chronic anterior uveitis (iritis) demonstrating localised limbal Ciliary injection and posterior synechia with irregular pupil. This patient has sarcoidosis and secondary cataract formation is also present.

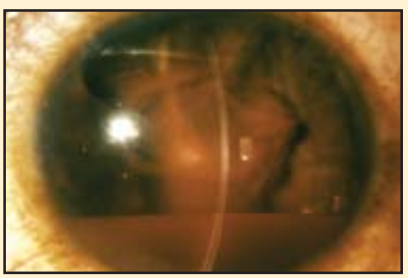

Figure 9. Traumatic Hyphaema demonstrating the horizontal line separating blood from aqueous and in this situation an additional clot superiorly.

characteristic branching dendritic appearance, with generalised mild conjunctival hyperaemia. Marginal ulceration will occur adjacent to the limbus with localised conjunctival hyperaemia. The treatment of choice for herpetic ulceration is topical aciclovir, whilst the treatment of marginal ulceration is combined topical antibiotic and steroid. Unfortunately the latter treatment, if used for herpetic ulceration, could result in significant exacerbation and for this reason slit-lamp evaluation is necessary.

9. Blunt trauma

The history of trauma directly to the eye with resulting loss of visual function requires appropriate evaluation and referral as indicated. Corneal abrasion is very painful, and is accompanied by intense lacrimation. Instillation of topical anaesthetic agent will result in symptomatic improvement, and will allow further evaluation. Loss of visual acuity will often be dramatically improved with pinhole testing, and direct observation of the cornea with fluorescein stain will confirm the diagnosis. Treatment with topical antibiotic ointment and firm patching will usually result in rapid healing over two to four days. Additional comfort is aided by the use of a topical mydriatic and systemic analgesia. A long-term complication is recurrent erosion syndrome manifested by intense pain and lacrimation on awakening. Additional indications of blunt trauma to the eye include traumatic mydriasis, and attention to ocular motility to exclude blow-out orbital floor fractures.

The presence of blood in the anterior chamber (hyphaema) indicates significant damage to ocular structures with the risk of short-term complication of re-bleeding and long-term complication of secondary eye disorders such as cataract and glaucoma. These patients require specialist review that day and often will require short-term hospitalisation. (Figure 9)

10. Chemical trauma

Typical history of splashing either acidic or alkali agents into the eye, with severe pain, lacrimation, and loss of visual acuity. Even if the patient has already been rendered first aid treatment with washing out the eye, this should be repeated copiously with saline solution . The use of topical anaesthetic will improve patient comfort. Acid agents tend to coagulate on the corneal surface, whilst alkali agents penetrate the cornea causing serious ocular damage. Corneal oedema, opacity, and conjunctival blanching are poor prognostic signs and urgent specialist referral is necessary.

Conclusion

In many situations the history will have alerted the general practitioner to potential ophthalmic emergency presentations. Appropriate evaluation including measuring visual acuity both unaided and with pinhole, examination of the pupils, anterior segment with flashlight, and fundoscopy with direct ophthalmoscopy will result in the formulation of a differential diagnosis. Appropriate initial treatment may then affect the long-term outcome and timely referral to specialist care will result. A quick phone call to an ophthalmologist should confirm the best option for the patient!